

Mycobacterial infections in cats and dogs

Jordan L. Mitchell & Daniëlle A. Gunn-Moore

To cite this article: Jordan L. Mitchell & Daniëlle A. Gunn-Moore (2019) Mycobacterial infections in cats and dogs, Veterinary Nursing Journal, 34:4, 102-107, DOI: [10.1080/17415349.2018.1551103](https://doi.org/10.1080/17415349.2018.1551103)

To link to this article: <https://doi.org/10.1080/17415349.2018.1551103>



Published online: 14 Mar 2019.



Submit your article to this journal [↗](#)



Article views: 98



View related articles [↗](#)



View Crossmark data [↗](#)



Jordan Mitchell BVM&S, MRCVS

Jordan graduated with distinction from The University of Edinburgh in 2015 before spending time in small animal general practice, developing interests in feline medicine, anatomic pathology and cytology. He returned to Edinburgh in October 2017 to start a PhD looking into the immunopathology and diagnostics of feline tuberculosis. Email: jordan.mitchell@ed.ac.uk




Danièle Gunn-Moore BSc (Hons), BVM&S, PhD, MANZCVS, FHEA, FRFB, FRCVS, RCVS Specialist in Feline Medicine

An internationally recognised expert in Feline Medicine, Danièle graduated from Edinburgh in 1991. A Scholarship and Fellowship at The University of Bristol's Feline Centre followed, where she also completed a PhD study into FIP in 1997. She returned to Edinburgh, establishing the Feline Clinic and became Professor of Feline Medicine in 2006. Email: danielle.gunn-moore@ed.ac.uk

DOI: 10.1080/17415349.2018.1551103

Mycobacterial infections in cats and dogs

Jordan L. Mitchell BVM&S, MRCVS 

Danièle A. Gunn-Moore BSc (Hon), BVM&S, PhD, MANZCVS, FHEA, FRFB, FRCVS, RCVS Specialist in Feline Medicine 

Royal (Dick) School of Veterinary Studies and The Roslin Institute, The University of Edinburgh, Easter Bush, Midlothian, UK

ABSTRACT: Mycobacterial infections in cats and dogs are often overlooked in veterinary practice, despite representing a significant risk to the health of both animals and people. This paper will review the most important features of companion animal mycobacteriosis, focusing on tuberculosis (TB), as it is seen commonly in cats in the UK. The underlying epidemiology of mycobacterial infections, their clinical presentations, diagnostic options and the principles of treatment are discussed, as well as the zoonotic risk these infections may pose, and the key role the veterinary nursing team can play in the care of these patients.

Keywords: mycobacteria; tuberculosis; cats; dogs; zoonosis

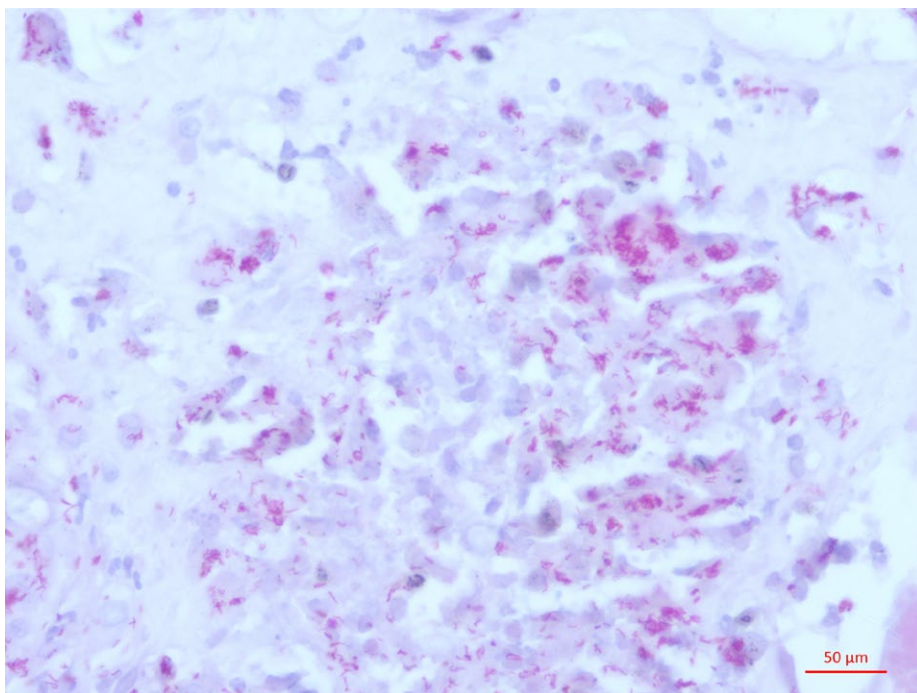
Introduction

Mycobacteria are curved, slender, rod-shaped bacteria that are often slow-growing, and are responsible for two of the most well-known diseases in human history: tuberculosis (TB) and leprosy. In veterinary species, mycobacterial disease is not limited to cattle and badgers; in fact, mycobacterial infections have been reported in companion animal species since the late nineteenth century (Jensen, 1891) and a recent outbreak of TB in a pack of foxhounds in England has shown that we need to be continually aware of the potential for these infections (O'Halloran et al., 2018). In Great Britain, among companion animal species mycobacterial infections are significantly more common in cats than dogs (Broughan et al., 2013).

Epidemiology

In Great Britain, of all the feline biopsies submitted for histopathology, approximately 1% show signs indicative of mycobacterial infection, suggesting a substantial burden of disease among the domestic cat population. Of these, one-third are positive on Ziehl-Neelsen (ZN) staining for acid-fast bacilli (AFB), morphologically consistent with mycobacteria (Figure 1) (Gunn-Moore, Gaunt, & Shaw, 2013).

Broadly speaking, the potentially pathogenic mycobacteria can be categorised into two groups: the *Mycobacterium tuberculosis*-complex (MTBC) and the non-tuberculous mycobacteria (NTM) (Gunn-Moore, McFarland, Brewer, et al., 2011). The MTBC comprises 10 closely related mycobacteria which cause TB across many species; those identified as causing clinical disease in cats include *M. bovis*, better known as the causative agent of TB in cattle, and *M. microti*, which typically causes TB in small rodents (O'Halloran & Gunn-Moore, 2017). Based on bacterial culture, one-third of feline mycobacteriosis cases are attributable to MTBC infection; 19% of submissions successfully cultured *M. microti* compared to 15% for *M. bovis* (Gunn-Moore, McFarland, Brewer, et al., 2011). The main cause of human TB, *M. tuberculosis*, has not been shown to cause clinical disease in cats (Francis, 1958; Smith, 1964); this is not the case with dogs (Engelmann, Ondreka, Michalik, & Neiger, 2014; Ribeiro et al., 2017), which are susceptible to this infection, along with *M. bovis*, whereas *M. microti* has rarely been isolated from dogs (Deforges et al., 2004). Regarding the NTM, some species cannot be cultured in the laboratory, so are designated as causing "feline leprosy syndrome" (FLS), while others



▲ **Figure 1.** Ziehl-Neelsen stain showing vast numbers of intracellular acid-fast bacilli in a cutaneous feline tuberculosis lesion (*M. microti*) (×400 magnification).

can be cultured and are termed “atypical mycobacteriosis” or “opportunistic mycobacteriosis”. However, as molecular diagnostic methods improve, the distinction between these disease entities is narrowing. The most common NTM of cats in Great Britain, based on culture, is *M. avium* (Gunn-Moore, Mcfarland, Brewer, et al., 2011).

In Great Britain, feline infections with different mycobacterial species cluster to distinct regions. Unsurprisingly, *M. bovis* infections appear coincident with high levels of endemic infection within cattle (Gunn-Moore, Mcfarland, Brewer, et al., 2011), i.e. the south-west of England and Wales, whereas *M. microti* is predominant

in regions with high levels of infection in the local wild rodent population (Burthe et al., 2008), i.e. the south-east and north of England, and Scotland, which is recognised as officially bovine TB-free.

Regarding risk factors, male cats with outdoor access, and those that hunt have been identified as being at greatest risk of becoming infected. The median age for infection is three years for *M. bovis* and eight years for *M. microti* (Gunn-Moore, Mcfarland, Brewer, et al., 2011). Obesity is a risk factor for infections with lipophilic NTM species, such as *M. fortuitum* and *M. smegmatis* (Malik et al., 2000), which may contaminate wounds occurring in fat pads, notably the abdominal “apron

fat” (Ålander-Damsten et al., 2003). Cats with mycobacterial infections rarely show signs of classical immunosuppression with either FIV or FeLV (Gunn-Moore, Jenkins, & Lucke, 1996), but Siamese (Jordan, Cohn, & Armstrong, 1994) and Abyssinian cat breeds (Baral et al., 2006) are overrepresented for *M. avium* infections.

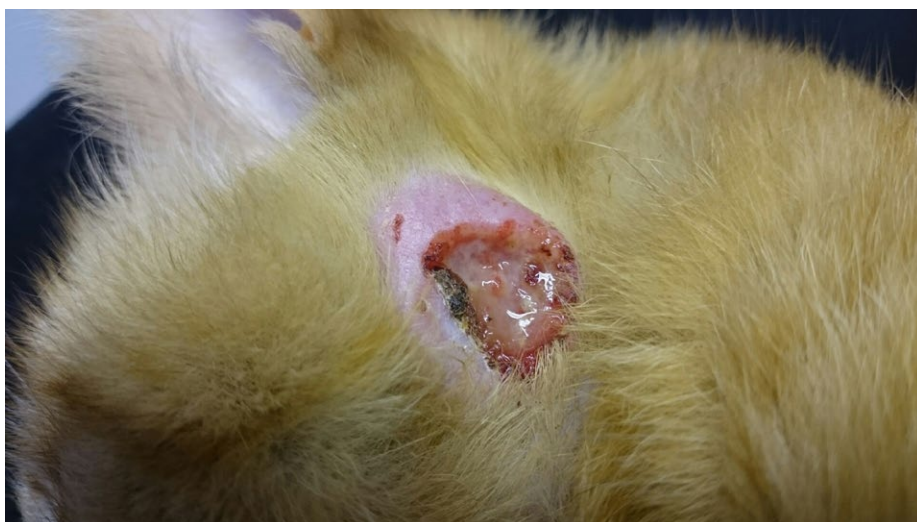Clinical signs

The most common presentation of feline mycobacterial disease is localised, nodular, cutaneous disease (Gunn-Moore, Mcfarland, Brewer, et al., 2011). Skin masses can vary in size, may be ulcerated (Figure 2) and/or have discharging sinus tracts; they are typically found in “fight and bite” sites, i.e. the face, limbs, perineum and tail base (Gunn-Moore, 2014). Lesions are thought to arise from injuries when cats hunt and/or play with rodent prey. Local lymph nodes may also be enlarged and in some cases a generalised lymphadenopathy is observed (O’Halloran & Gunn-Moore, 2017). Occasionally, an “incomplete primary complex” is noticed, where there is lymph node involvement but no obvious associated skin lesion. Both MTBC and NTM infections can result in grossly similar nodular cutaneous lesions, making it impossible to distinguish between these two groups of mycobacteria by clinical signs alone (Malik et al., 2013).

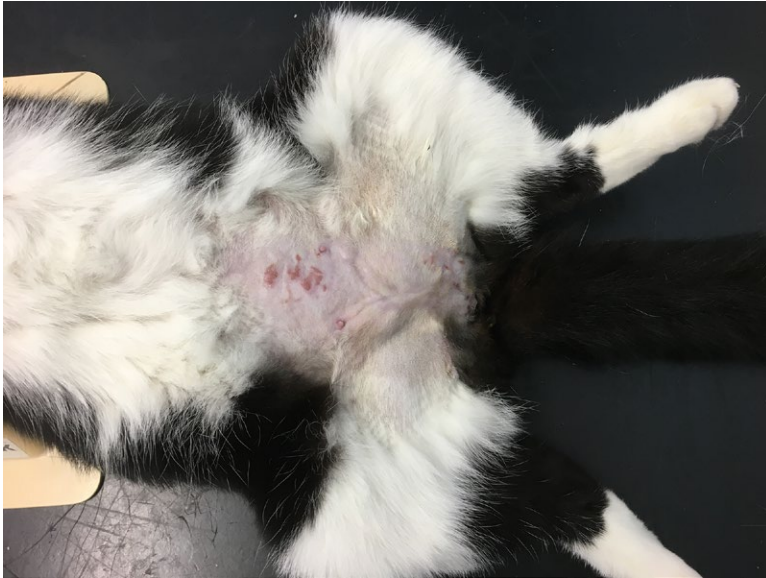Primary respiratory TB is uncommon in cats; however, secondary spread of tuberculous bacteria from cutaneous lesions, presumptively via haematogenous routes, to the lungs is seen often, resulting in diffuse interstitial pulmonary disease. Clinical signs may not be recognised until there is further progression of disease resulting in bronchial infiltration and the development of dyspnoea and a soft cough (Gunn-Moore, Mcfarland, Brewer, et al., 2011; Gunn-Moore et al., 1996).

Since the routine pasteurisation of cows’ milk, and TB testing of the national herd, the burden of gastrointestinal TB has dramatically decreased, although cases are still infrequently recognised (Gunn-Moore, 2014). Granulomas develop throughout the intestinal tract and mesenteric lymph nodes, resulting in non-specific signs such as vomiting, diarrhoea and weight loss (Gunn-Moore, 2014).

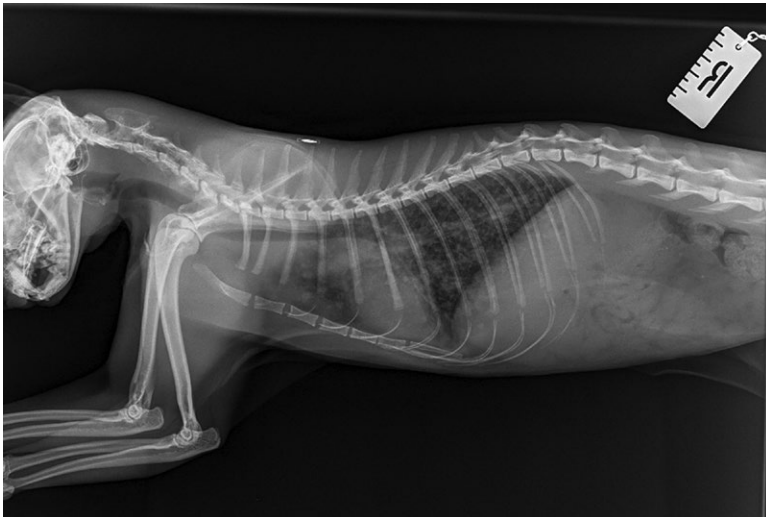
Other sites that can become infected include the joints (Lalor et al., 2017), the eyes (Formston, 1994) and the



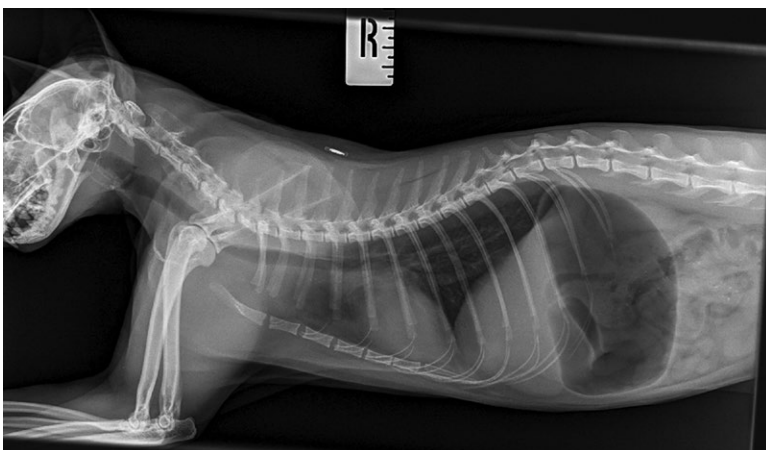▲ **Figure 2.** An ulcerative, nodular lesion on the head of the cat; a typical presentation of feline tuberculosis (*M. microti*). (Image courtesy of Conor O’Halloran and Professor Jayne Hope.)



▲ **Figure 3.** Granulomatous panniculitis resulting from infection with a lipophilic non-tuberculous mycobacterial species. (Image courtesy of Paul Saunders.)



▲ **Figure 4.** Right lateral thoracic radiograph showing a diffuse, interstitial pulmonary pattern. A diagnosis of *M. microti* was made on interferon-gamma release assay. (Image courtesy of Gillian McLeod.)



▲ **Figure 5.** Follow-up radiograph of the same cat three months post-treatment with rifampicin, pradofloxacin and azithromycin, showing resolution of radiographic pulmonary signs. (Image courtesy of Gillian McLeod.)

central nervous system (Madarama et al., 2017), resulting in multiple clinical signs such as soft tissue swelling and lameness, uveitis and blindness and neurological deficits. If disease becomes disseminated, pericardial, pleural or abdominal effusions may develop and there may also be hepatosplenomegaly (Gunn-Moore, 2014).

One presentation of mycobacterial disease that appears unique to some lipophilic NTM species is panniculitis, often in the inguinal region, with lesions having a “salt-and-pepper shaker” appearance (Ålander-Damsten et al., 2003; Malik et al., 2000). There can be multiple punctate draining tracts and areas of ulceration (Figure 3), which may coalesce to form larger areas of non-healing tissue. These can be painful and the affected cat may be lethargic and reluctant to move (Gunn-Moore, 2014).

The clinical description of canine mycobacteriosis is less well described, but cases predominantly present with severe, disseminated multi-organ disease, often with renal or pulmonary involvement (Jensen, 1891; O’Halloran et al., 2018; Snider, 1971).

Diagnosis

Even though many different mycobacterial infections can present with similar clinical signs, obtaining a definitive diagnosis should always be attempted as different species of mycobacteria respond better to certain antimicrobial protocols and carry different zoonotic risk (Gunn-Moore, 2014). Current legislation states the suspicion of TB on post-mortem examination of a pet mammal is notifiable to the Animal and Plant Health Agency (APHA), although suspected TB in a living pet is not notifiable (O’Halloran & Gunn-Moore, 2017). Routine haematology and serum biochemistry should be run to provide baseline values prior to treatment. Hypercalcaemia may be identified, which is a poor prognostic indicator (Baral et al., 2006; Gunn-Moore, Mcfarland, Brewer, et al., 2011). Determining the extent of pulmonic involvement with thoracic radiographs (or CT) should be performed early during investigations (Figure 4). An interstitial pattern is seen initially, which can become bronchial if disease is left to progress (Bennett, Lator, Schwarz, & Gunn-Moore, 2011; Major et al., 2016). Follow-up imaging is advisable to assess response to treatment (Figure 5).

Depending on the presentation, imaging of other body regions may be indicated, and FeLV/FIV screening is recommended (Gunn-Moore, 2014).

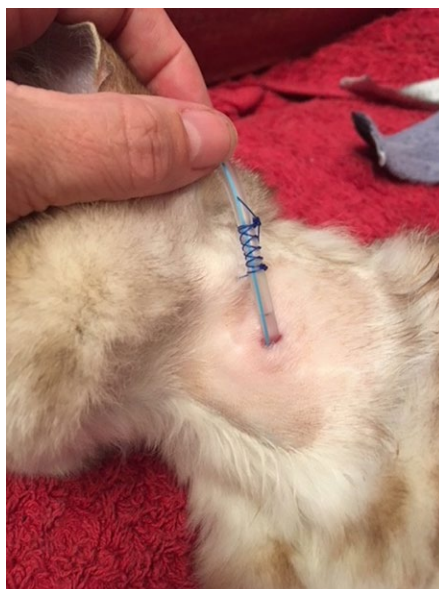In-house cytology of nodular lesions can be performed to exclude neoplasia and unstained cytological smears should be stored for PCR testing, if this is later indicated (O'Halloran & Gunn-Moore, 2017). The most frequent method of obtaining a diagnosis is via skin lesion biopsy; these should be bisected, with half formalin-fixed for histopathology and the other half retained and frozen for further testing if required (O'Halloran & Gunn-Moore, 2017). Histopathology classically shows granulomatous inflammation, predominated by macrophages, with frequent neutrophils and variable degrees of necrosis (Gunn-Moore, Mcfarland, Schock, et al., 2011). ZN-staining may reveal variable numbers of AFB, of which mycobacteria are the main presenting species, but a negative ZN stain does not rule out mycobacterial disease (Gunn-Moore et al., 2013).

Specialist mycobacterial culture is the reference standard diagnostic test which can identify the exact mycobacterial species present; however, the sensitivity is only 50% and it takes on average three months (Smith, Crawshaw, Parry, & Birtles, 2009). While awaiting results of culture, empirical treatment should be commenced.

Other diagnostic tests include the interferon gamma (IFN- γ) release assay (IGRA) (Rhodes et al., 2008a, 2008b) and polymerase chain reaction (PCR) (Aranaz et al., 1996). The IGRA uses leucocytes isolated from a heparinised whole-blood sample (neither chilled/frozen nor spun), which are stimulated to produce IFN- γ ; this test has excellent sensitivity for identifying MTBC infections (Rhodes et al., 2011). PCR diagnostics are becoming increasingly available and unstained cytological smears and fresh tissue currently provide better chances of getting a result than formalin-fixed tissues (Reppas et al., 2013).

Treatment and prognosis

Treating a case of mycobacterial disease can be lengthy, challenging, and sometimes contentious; owners should be made aware of this before commencing any protocol. Some of the drugs used have potentially serious side effects and to maximise the chance of a successful



▲ **Figure 6.** Placement of an oesophagostomy tube to facilitate medication. The tube is sutured to the wing of the axis and the periosteum behind the ear to prevent movement and displacement. The tube is then cut off short and the end banded. A soft collar may be worn over it. The cat can then go out as it wishes.

Note: the suture is placed away from the wound, facilitating cleaning of the site. (Image courtesy of Tina Coventry.)

outcome there needs to be good patient and owner compliance. A knowledgeable RVN can provide the time to have these lengthy and complex conversations with owners to offer practical guidance on how to care for these patients at home, methods for administering medication and the risk of infection to others. Long-term remission has been reported at 40% (Gunn-Moore, Mcfarland, Schock, et al., 2011), but many cases in that study were treated suboptimally (inappropriate antibiotics and/or duration of treatment and/or monotherapy). Where appropriate treatment has been undertaken, success rates approaching 90% have been achieved with some cutaneous NTM infections (O'Brien et al., 2017) and 70–80% success has been recorded in cases of cutaneous TB with or without pulmonary involvement (O'Halloran & Gunn-Moore, 2017).

The recommended treatment for feline TB is triple therapy comprising rifampicin (Rifadin, Sanofi), pradofloxacin (Veraflox, Bayer) and azithromycin (Zithromax, Pfizer). This combination allows for once-daily dosing with all three drugs being given together (O'Halloran & Gunn-Moore, 2017).

Treatment protocol lengths of 4–6 months are recommended, depending on the extent of disease, with treatment given for at least two months post-resolution of clinical signs, including radiographic changes (Gunn-Moore, 2014). To improve patient compliance, an oesophagostomy tube can be placed for administering medication, which makes treatment less stressful for the patient and the owner (Figure 6).

Prior to commencing antimicrobial treatment it is highly recommended to take blood for haematology and serum biochemistry to provide a baseline of values to compare against later if side effects are seen. This is because while rifampicin is an excellent anti-mycobacterial drug, it can be hepatotoxic (O'Halloran & Gunn-Moore, 2017). Other side effects include anorexia, pruritus, hyperaesthesia and discolouration of bodily fluids to orange–red, which owners should be made aware of. High doses and/or long courses of pradofloxacin can cause neutrophil counts to fall (Plumb, 2015).

When treating NTM infections, the specific infectious agent will influence the choice of drug protocol as there can be wide variability in the drug resistance and susceptibility profiles between and within mycobacterial species (Gunn-Moore, 2014). Clarithromycin (generic) and doxycycline (Doxycycline Monohydrate, Bova) are often used in place of azithromycin and pradofloxacin (O'Halloran & Gunn-Moore, 2017).

Surgery may be indicated in some cases of TB and NTMs (e.g. small, discrete nodules with no discharging tracts) and this may be curative, although adjunctive antimicrobial therapy is advised (Gunn-Moore, Mcfarland, Schock, et al., 2011). In cases of articular TB a combination of radical surgery (i.e. amputation) in conjunction with antimicrobial therapy is recommended (Lalor et al., 2017).

If there is evidence of severe disseminated disease in a systemically unwell patient, euthanasia is a sensible option, especially with TB (O'Halloran & Gunn-Moore, 2017). Dogs are more likely to present with systemic signs and are notoriously more difficult to treat, possibly because they present with severe disseminated disease; hence, most cases are euthanised (O'Halloran et al., 2018). Due to the risk to human health, all

cases of *M. tuberculosis* infection should be euthanised and the body cremated (Ribeiro et al., 2017).

Patient care and zoonotic risk

Caring for a patient with mycobacterial disease need not be a daunting prospect. While potentially zoonotic (Roberts, Connor, Nuñez-García, De La Rua-Domenech, & Smith, 2014), the risk to human health of infection with *M. bovis*, the most zoonotic mycobacteria encountered in cats, is deemed very low by public health bodies (Human Animal Infections & Risk Surveillance Group, 2014); in over 150 years there have only been six recorded occasions of cats infecting humans globally, with purulent draining lesions in each case (Gunn-Moore & Lalor, 2015). If a cat is suspected of, or is diagnosed as having, TB and the patient requires hospitalisation, it does not need to go into isolation provided appropriate protection is worn, i.e. gloves and apron, when handling the patient. However, if there are discharging lesions then the zoonotic risk is more serious and isolation is advised. Carers should wear a mask in addition to gloves and an apron. Hospital-acquired infections to other animals in the clinic are also possible when wet TB-infected wounds are present (Murray et al., 2015), so good hygiene protocols must be in place to minimise this risk, including use of mycobactericidal disinfectants, e.g. Anistel. The potential zoonotic risk will vary depending on where in the country the pet came from; if from areas where there is no *M. bovis*, zoonotic risk is exceedingly low; however, if it comes from an area where *M. bovis* is seen in cattle and badgers (Gunn-Moore, McFarland, Brewer, et al., 2011), and there are draining skin lesions and/or significant pulmonary or gastrointestinal disease, the risk has to be considered as more serious (O'Halloran & Gunn-Moore, 2017).

The nursing team can provide an invaluable resource for educating owners about these infections, and on the care of oesophagostomy tubes, if one is placed, as well as providing regular weight checks as part of the monitoring process both during and after treatment. Teaching owners how to assess the resting respiratory rate of their pet at home is a useful tool for monitoring patients post-treatment, as subtle changes have been identified

with recurrence of infection (Major et al., 2018).

Summary

Mycobacterial infections are increasingly recognised in companion animal species, especially cats, and they can cause a significant burden of disease. Nodular cutaneous lesions are the most common presentation of disease in cats and mycobacteriosis should be considered as a differential diagnosis for any dermatological case not responding to conventional treatment. Appropriate antimicrobial therapy can yield long-term resolution for many feline mycobacterial infections. However, canine mycobacteriosis carries a substantially poorer prognosis.

Acknowledgements

We would like to thank the clinicians, veterinary nurses, owners and pets who have contributed to ongoing research into mycobacterial disease at The University of Edinburgh.

Disclosure statement

No potential conflict of interest was reported by the author(s).

Funding

This work was supported by the Biotechnology and Biological Sciences Research Council (BBSRC) under Grant [BB/M010996/1].

ORCID

Jordan L. Mitchell  <http://orcid.org/0000-0001-6755-3214>

Danielle A. Gunn-Moore  <http://orcid.org/0000-0003-2088-503X>

References

- Ålander-Damsten, Y. K., Brander, E. E., & Paulin, L. G. (2003). Panniculitis, due to *Mycobacterium smegmatis*, in two Finnish cats. *Journal of Feline Medicine and Surgery*, 5(1), 19–26.
- Aranaz, A., Liébana, E., Pickering, X., Novoa, C., Mateos, A., & Domínguez, L. (1996). Use of polymerase chain reaction in the diagnosis of tuberculosis in cats and dogs. *The Veterinary Record*, 138(12), 276–280.
- Baral, R. M., Metcalfe, S. S., Krockenberger, M. B., Catt, M. J., Barrs, V. R., McWhirter, C., ... Malik, R. (2006). Disseminated *Mycobacterium avium* infection in young cats: overrepresentation of Abyssinian cats. *Journal of Feline Medicine and Surgery*, 8(1), 23–24.
- Bennett, A. D., Lalor, S., Schwarz, T., & Gunn-Moore, D. A. (2011). Radiographic findings in cats with mycobacterial infections. *Journal of Feline Medicine and Surgery*, 13(10), 718–724.
- Broughan, J. M., Downs, S. H., Crawshaw, T. R., Upton, P. A., Brewer, J., & Clifton-Hadley, R. S. (2013). *Mycobacterium bovis* infections in domesticated non-bovine mammalian species. Part 1: Review of epidemiology and laboratory submissions in Great Britain 2004–2010. *The Veterinary Journal*, 198(2), 339–345.
- Burthe, S., Bennett, M., Kipar, A., Lambin, X., Smith, A., Telfer, S., & Begon, M. (2008). Tuberculosis (*Mycobacterium microti*) in wild field vole populations. *Parasitology*, 135, 309–317.
- Deforges, L., Boulouis, H. J., Thibaud, J. L., Boulouha, L., Sougakoff, W., Blot, S., ... Haddad, N. (2004). First isolation of *Mycobacterium microti* (Llama-type) from a dog. *Veterinary Microbiology*, 103(3–4), 249–253.
- Engelmann, N., Ondreka, N., Michalik, J., & Neiger, R. (2014). Intra-abdominal *Mycobacterium tuberculosis* Infection in a Dog. *Journal of Veterinary Internal Medicine*, 28(3), 934–938.
- Formston, C. (1994). Retinal detachment and bovine tuberculosis in cats. *Journal of Small Animal Practice*, 35(1), 5–8.
- Francis, J. (1958). *Tuberculosis in animals and man: A study in comparative pathology*. London: Cassell.
- Gunn-Moore, D. A. (2014). Feline mycobacterial infections. *Veterinary Journal (London, England : 1997)*, 201(2), 230–238.
- Gunn-Moore, D. A., Gaunt, C., & Shaw, D. J. (2013). Incidence of mycobacterial infections in cats in Great Britain: Estimate from feline tissue samples submitted to diagnostic laboratories. *Transboundary and Emerging Diseases*, 60(4), 338–344.
- Gunn-Moore, D. A., Jenkins, P. A., & Lucke, V. M. (1996). Feline tuberculosis: A literature review and discussion of 19 cases caused by an unusual mycobacterial variant. *Veterinary Record*, 138(3), 53.
- Gunn-Moore, D. A., & Lalor, S. (2015). Tuberculosis in Companion Animal Species. In: Mukundan, H., Chambers, M. A., Waters, W. R., & Larsen, M. H. (Eds.), *Tuberculosis, leprosy and mycobacterial diseases of man and animals: The many hosts of mycobacteria*. Wallingford, UK: CAB International.
- Gunn-Moore, D. A., McFarland, S. E., Brewer, J. I., Crawshaw, T. R., Clifton-Hadley, R. S., Kovalik, M., & Shaw, D. J. (2011). Mycobacterial disease in cats in Great Britain: I. Culture results, geographical distribution and clinical presentation of 339 cases. *Journal of Feline Medicine and Surgery*, 13(12), 934–944.
- Gunn-Moore, D. A., McFarland, S. E., Schock, A., Brewer, J. I., Crawshaw, T. R., Clifton-Hadley, R. S., & Shaw, D. J. (2011). Mycobacterial disease in a population of 339 cats in Great Britain: II. Histopathology of 225 cases, and treatment and outcome of 184 cases. *Journal of Feline Medicine and Surgery*, 13(12), 945–952.
- Human Animal Infections and Risk Surveillance Group (HAIRS). (2014). Qualitative assessment of the risk that cats infected with *Mycobacterium bovis* pose to human health. Public Health England.
- Jensen, C. O. (1891). Tuberculosis in the dog and cat. *Journal of Comparative Pathology and Therapeutics*, 4, 103–125.
- Jordan, H. L., Cohn, L. A., & Armstrong, P. J. (1994). Disseminated *Mycobacterium avium* complex infection in three Siamese cats. *Journal of the American Veterinary Medical Association*, 204, 90–93.
- Lalor, S. M., Clark, S., Pink, J., Parry, A., Scurrell, E., Fitzpatrick, N., ... Gunn-Moore, D. (2017). Tuberculosis joint infections in four domestic cats. *JFMS Open Reports*, 3, 1–8.
- Madarama, H., Saito, M., Ogihara, K., Ochiai, H., Oba, M., Omatsu, T., ... Mizutani, T. (2017). *Mycobacterium avium* subsp. *hominissuis* meningoencephalitis in a cat. *Veterinary Microbiology*, 204, 43–45.

Major, A., Holmes, A., Warren-Smith, C., Lalor, S., Littler, R., Schwarz, T., & Gunn-Moore, D. (2016). Computed tomographic findings in cats with mycobacterial infection. *Journal of Feline Medicine and Surgery*, 18(6), 510–517.

Major, A., O'Halloran, C., Holmes, A., Lalor, S., Littler, R., Spence, S., ... Gunn-Moore, D. (2018). Use of computed tomography imaging during long-term follow-up on nine feline tuberculosis cases. *Journal of Feline Medicine and Surgery*, 20(2), 189–199.

Malik, R., Smits, B., Reppas, G., Laprie, C., O'Brien, C., & Fyfe, J. (2013). Ulcerated and nonulcerated nontuberculous cutaneous mycobacterial granulomas in cats and dogs. *Veterinary Dermatology*, 24(1), 146–153.

Malik, R., Wigney, D. I., Dawson, D., Martin, P., Hunt, G. B., & Love, D. N. (2000). Infection of the subcutis and skin of cats with rapidly growing mycobacteria: A review of microbiological and clinical findings. *Journal of Feline Medicine and Surgery*, 2(1), 35–48.

Murray, A., Dineen, A., Kelly, P., Mcgoey, K., Madigan, G., Nighallchoir, E., & Gunn-Moore, D. A. (2015). Nosocomial spread of *Mycobacterium bovis* in domestic cats. *Journal of Feline Medicine and Surgery*, 17(2), 173–180.

O'Brien, C. R., Malik, R., Globan, M., Reppas, G., Mccowan, C., & Fyfe, J. A. (2017). Feline leprosy due to *Mycobacterium lepraemurium*: Further clinical and

molecular characterisation of 23 previously reported cases and an additional 42 cases. *Journal of Feline Medicine and Surgery*, 19, 737–746.

O'Halloran, C., & Gunn-Moore, D. (2017). Mycobacteria in cats: An update. *In Practice*, 39, 399.

O'Halloran, C., Hope, J. C., Dobromylskij, M., Burr, P., McDonald, K., Rhodes, S., ... Gunn-Moore, D. A. (2018). An outbreak of tuberculosis due to *Mycobacterium bovis* infection in a pack of English Foxhounds (2016–2017). *Transboundary and Emerging Diseases*, 65(6), 1872–1884.

Plumb, D. C. (2015). *Veterinary drug handbook*. New York: John Wiley & Sons Inc.

Reppas, G., Fyfe, J., Foster, S., Smits, B., Martin, P., Jardine, J., ... Malik, R. (2013). Detection and identification of mycobacteria in fixed stained smears and formalin-fixed paraffin-embedded tissues using PCR. *Journal of Small Animal Practice*, 54(12), 638–646.

Rhodes, S. G., Gruffydd-Jones, T., Gunn-Moore, D., & Jahans, K. (2008a). Adaptation of IFN-gamma ELISA and ELISPOT tests for feline tuberculosis. *Veterinary Immunology and Immunopathology*, 124(3–4), 379–384.

Rhodes, S. G., Gruffydd-Jones, T., Gunn-Moore, D., & Jahans, K. (2008b). Interferon-gamma test for feline tuberculosis. *The Veterinary Record*, 162(14), 453–454.

Rhodes, S. G., Gunn-Moore, D., Boschiroli, M. L., Schiller, I., Esfandiari, J., Greenwald, R., & Lyashchenko, K. P. (2011). Comparative study of IFN- γ and antibody tests for feline tuberculosis. *Veterinary Immunology and Immunopathology*, 144(1–2), 129–134.

Ribeiro, G. M., Lima, M. C. F., Franco, M. M. J., Megid, J., Soares, L. M., Machado, L. H. A., ... Paes, A. C. (2017). Pre-multidrug-resistant *Mycobacterium tuberculosis* infection causing fatal enteric disease in a dog from a family with history of human tuberculosis. *Transboundary and Emerging Diseases*, 64(5), e4–e7.

Roberts, T., Connor, C., Nuñez-García, J., De La Rúa-Domenech, R., & Smith, N. H. (2014). Unusual cluster of *Mycobacterium bovis* infection in cats. *Veterinary Record*, 174, 326–328.

Smith, J. E. (1964). Symposium on diseases of cats—III. Some pathogenic bacteria of cats with special reference to their public health significance. *Journal of Small Animal Practice*, 5(6), 517–524.

Smith, N. H., Crawshaw, T., Parry, J., & Birtles, R. J. (2009). *Mycobacterium microti*: More diverse than previously thought. *Journal of Clinical Microbiology*, 47(8), 2551–2559.

Snider, W. R. (1971). Tuberculosis in canine and feline populations: Review of the literature. *The American Review of Respiratory Disease*, 104, 877–887.

Multiple Choice Questions

- Which of the following bacterial morphologies describes mycobacteria?
 - Chains of cocci
 - Curved and rod-shaped
 - Spirochetes
 - Clusters of cocci
- Which two human diseases are caused by mycobacteria?
 - Tuberculosis and leprosy
 - Tuberculosis and leptospirosis
 - Leptospirosis and brucellosis
 - Leptospirosis and leprosy
- Primary respiratory TB is uncommon in cats
 - True
 - False
- The most common presentation of feline mycobacterial disease consists of which of the following clinical signs?
 - Coughing and dyspnoea
 - Conjunctivitis and nasal discharge
 - Anorexia, lethargy and ascites
 - Nodular skin masses
- Currently the recommended treatment for feline TB is triple antibiotic therapy consisting of which combination of drugs?
 - Rifampicin, pradofloxacin and azithromycin
 - Rifampicin, doxycycline and meloxicam
 - Pradofloxacin, metoclopramide and meloxicam
 - Pradofloxacin, acepromazine and trilostane
- What is the current duration for treatment using the triple therapy approach for feline TB?
 - Four to six days and for at least two days post-resolution of clinical signs and radiographic changes
 - Four to six weeks and for at least two weeks post-resolution of clinical signs and radiographic changes
 - Four to six months and for at least two months post-resolution of clinical signs and radiographic changes
 - Four to six years and for at least two years post-resolution of clinical signs and radiographic changes
- A negative Ziehl-Neelsen stain does not rule out mycobacterial disease
 - True
 - False
- Which of the following histopathological descriptions is typical from a biopsy of a mycobacterial nodular skin mass?
 - Granulomatous inflammation predominated by erythrocytes
 - Granulomatous inflammation predominated by neutrophils
 - Granulomatous inflammation predominated by macrophages
 - Granulomatous inflammation predominated by eosinophils

For the answers to the MCQs, please go to: <http://www.bvna.org.uk/publications/veterinary-nursing-journal>